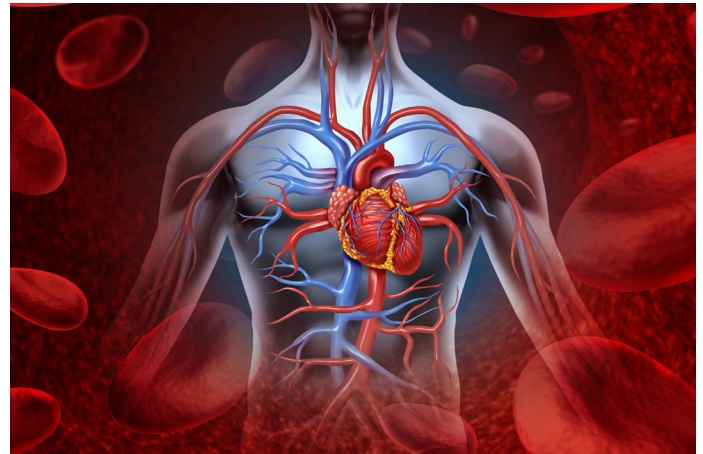



Coincidence High-Resolution and High-Sensitivity PET Imaging of Cardiovascular Disease: A Powerful Tool for Disease Imaging.

Jens Waldeck¹, Cesar Molinos¹, Willy Gsell², John O. Prior³, Uwe Himmelreich², David Viertl³

¹ Bruker BioSpin MRI GmbH, Rudolf-Plank-Str. 23, 76275 Ettlingen, Germany

² Biomedical MRI/MoSAIC, Katholieke Universiteit Leuven, Heerestraat 49, 3000 Leuven, Belgium

³ Centre Hospitalier Universitaire Vaudois (CHUV) Nuclear Medicine and Molecular Imaging Department, Rue du Bugnon 46, 1011 Lausanne, Switzerland

Abstract

Preclinical cardiac imaging requires high spatial and temporal resolution. The recent progress in preclinical multi-modal approaches and in particular PET/MRI makes nuclear imaging even more relevant in translational research. It has been stated that PET myocardial perfusion assessment under rest and stress for human patients is underutilized. Similarly, cardiac PET imaging investigating cardiac function in rodents is not used to its potential in part due to the perceived complexity of the method and past hardware limitations in spatial and temporal resolution as well as count rate performance. In this paper, we report the recent progress in preclinical PET hardware development enabling now to reach sub-millimeter resolution and high temporal accuracy needed for cardiac gated acquisitions.

Introduction

Patients that faced coronary artery diseases (CAD) strongly benefit from myocardial perfusion PET, as recently indicated by an ASNC/SNMMI position statement¹. However, as clearly stated myocardial PET imaging is still underused both in clinical and preclinical evaluation of cardiovascular diseases/models.

What is true for clinical imaging should, however, be also applied in preclinical set-ups as those finally aim to bridge the gap from translational research to clinical applications. Thus, one can advise researchers to apply those guidelines in a reverse from bench-to-bedside approach when applying small-animal non-invasive myocardial coincidence Positron Emission Tomography (mcPET) to gain confidence and security in separating disease stages from a normal physiological stage. The last point has its importance in the evaluation of therapeutic strategies and the determination of imaging biomarkers of CAD.

Many aspects of myocardial metabolism/perfusion balance and repair are currently explored in rodent models using either FDG/acetate as a surrogate marker of viability and metabolism² or index of inflammation via translocator protein TSPO tracers or poly-glucose nanoparticles²⁻⁴. However, quite often ECG-gated PET acquisitions are not performed in rodents due to its complexity and for time efficiency²⁻⁴, thus hampering the sensitivity of the detection due mainly to cardiac motion and to less extend to respiration⁵ but also somehow underestimating the PET signal true quantification (Fig. 1) and minimizing the local changes of myocardial FDG uptake⁶.

Figure 1

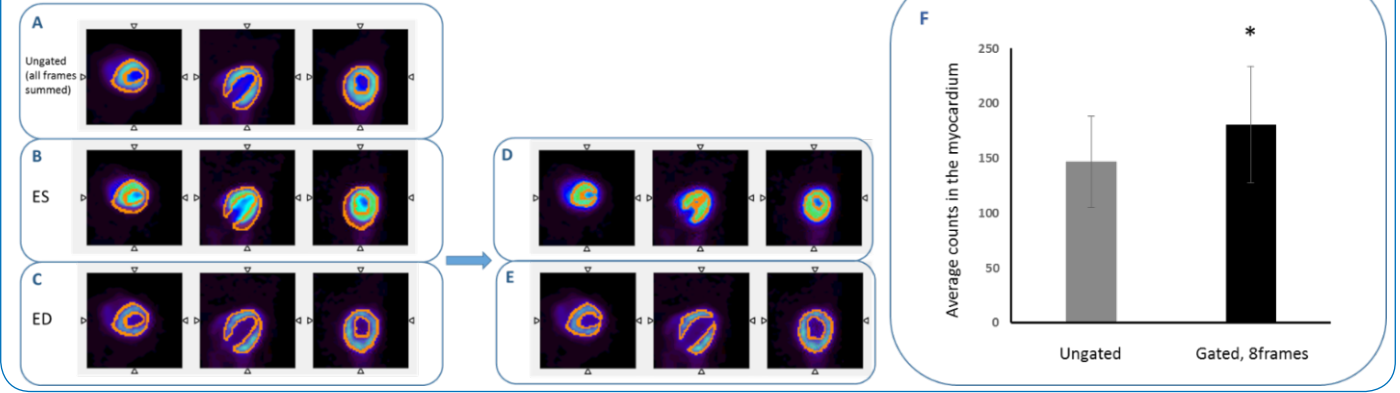


Figure 1: Error estimation in myocardial ¹⁸F-FDG uptake in mcPET acquisitions.

A: 3D isocontour determined from ungated ¹⁸F-FDG scan (summation of all cine frames). **B** and **C:** corresponding views of the same region of interest on the end systole (ES) and end diastole (ED). **D** and **E:** refined region of interest for ES and ED extracted from gated scan. The difference between gated and ungated estimation of myocardial FDG uptake resulted a significant underestimation of $22 \pm 6\%$ in the ungated evaluation compare to gated scan (* $P < 0,05$ paired t-test, $N = 7$).

Hardware Development Overcoming Limitations to Perform Cardiac Gated Acquisition in Rodents

In most mcPET scans, long scanning times, when synchronized with cardiac and respiration gating, are required to obtain usable information⁷. Thus, keeping the animal under very long anesthesia conditions and hence reducing the throughput. In preclinical imaging higher radiation doses per body weight have to be applied compared to human scanners due to the fact that not only the rodent metabolism is 5-6 times higher but also the size of a rodent heart is extraordinary smaller compared to human settings. Improvement of sensitivity of preclinical PET systems (e.g. up to 12 %; Albira Si PET) but also high efficiency count rate enables now to use low dose scans combined with relatively short acquisition times (20 min for an ECG gated scan reconstructed with 8-16 cine frames Fig. 2).

Figure 2

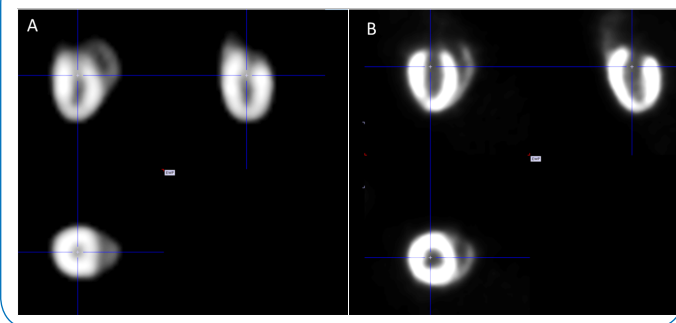


Figure 2: ECG-gated ¹⁸F-FDG cardiac PET images at end diastole in mouse (A) and rat (B) after 20 min acquisition.

Resolution is an important factor in cardiac imaging as it is often the case that blood concentration is obtained from the left ventricle. The higher the resolution, the lower the partial volume effect and therefore, less is the contamination from the myocardium into the blood concentration derived from imaging. Fig 3 shows the resolution achieved with some of today's scanner and in particular, when real time, true Depth of Interaction (DOI) information exists, the resolution can stay high across the full field of view. This opens up possibilities like multiple animal imaging where hearts are positioned away from the center of the scanner.

Figure 3

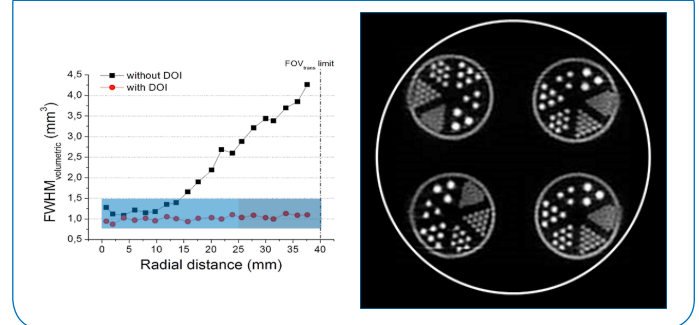


Figure 3: Albira Si high resolution regardless of position in the FOV.

Left: Resolution stays constant due to the accurate real time and true DOI (Depth of Interaction) correction. Right: Derenzo phantom imaged in 4 locations, capillaries are 0.75, 1.0, 1.35, 1.7, 2.0 and 2.4 mm.

These multi-factor high-power performances enables researchers to obtain results with low or ultra-low tracer activity ("safe") at high (diagnostic) accuracy ("sensitive") and in the shortest possible time ("efficient"). Scanning times are utmost important to be clinically-relevant (in daily routine 5-20 min) and thus to stay patient as well as cost-centered. Longer scanning times on ill or high-risk patients as well as on populations with overweighted BMIs would contradict a clinical translation of preclinical mcPET results. In addition, the convergence factor/

implication⁸ should not be underestimated, thus applying the best fitting methods to obtain (clinically) meaningful research results. Bruker enables researchers with these convenient mcPET solutions that uniquely combine excellent NEMA sensitivity paired with the measurable and non-simulated PET full-field of view accuracy (FFA), as well as sub-millimeter resolution. With these tools, the recommendations given by the ASNC and SNMMI, as well the Centers for Medicare & Medicaid Services (CMS) are now feasible with unprecedented accuracy. Indeed, the intrinsic resolution of the state-of-the-art preclinical PET scanners can now achieve sub-millimeter resolution enabling accurate detection of small lesions but also a better characterization of the right myocardial physiology, which is also affected in some pathologies such as pulmonary hypertension. It is also now more feasible to image smaller species such as mice in models that were previously only performed in rats, adding now the valuable use of genetically modified rodent strains.

In addition, the best in class NEMA sensitivity of 9% (12% iterative) reduces the user's risk by handling only very low radiation doses and subsequently reduces the dose applied (repeatedly) to the research/diagnosed subject and thus reflects the important human patients' safety concerns for "patients" with CAD, who will be repetitively exposed to radiation and thus get a summed up increased life-time person radiation dose. Here the ultimate goal to reduce the dose has to be applied in any research setting that claims to aim for a clinical translation. High doses can be detrimental during in vivo non-invasive imaging not only because of the above mentioned indications but also due to serious biological radiation effects. Those lead to erroneous conclusions, animal-care concerns and again a non-meaningful study set-up that is based on suspicious assumptions.

Multi-Modal Imaging Approaches

Bruker's PET/CT, in-line PET/MR and PET-Insert solutions allow uncompromised high-sensitivity and specificity measurements of all imaging modalities outperforming other non-invasive approaches. PET/CT has and is often still seen as the Gold-standard: The CT modality offers the ability to perform whole body anatomical imaging with a resolution of approximately 80-100 μm , therefore offering a detailed hard-tissue reference to PET images. CT is also used to correct PET images for photon attenuation and therefore extract quantitative parameters from PET⁹. Moreover, for cardiac application in murine models CT can provide complementary information such as calcification area and fine shape of vessel and cardiac structure. Recently usage of carbon nanotube was successfully applied in vivo to delineate calcification volume and plaque area in aortic arch and valves¹⁰. Finally, detailed angiography and cardiac morphology can be obtained using commercially available blood pool contrast agents such as Fenestra VC¹¹ or ExiTron nano 12000 (NanoPET, Berlin).

However, currently PET/MR is gaining more ground particularly in cardiac imaging. As with the PET/CT the Bruker PET/MR solutions are based on Bruker's state-of-the-art coincidence silicon PET (Si PET) detector innovations. Its unique continuous crystal design with precise DOI detection and advanced electronics with full row and column readout provides up to 0.7 mm resolution at Full Field Accuracy (FFA) and with 12% sensitivity¹². Its proven and already published ability to work in 15.2 T MR stray fields extends the Bruker Si PET technology up to high field MR either as a sequential in-line solution or as simultaneous PET/MR configuration. This already resulted in new areas of applications while enabling to combine the PET imaging read-out with complementary soft tissue information or in the form of simultaneous PET/MR in form of information gain such as global function through quantification of ejection fraction, cardiac output and wall thickening and precise localization of infarcted regions via late gadolinium enhanced techniques.

Subsequently, Bruker's MR information can also be used to further refine the way PET data are acquired or processed by using those a priori information in PET reconstruction with motion compensation using self-gated MRI (IntraGate®)¹³. Indeed, the use of the MRI information for retrospective cardiac/respiration gating without the use of ECG electrodes was recently demonstrated in rats and was one of the highlights of the last WMIC 2017 meeting in Philadelphia¹⁴ (Fig. 4). But one can also think of MRI-based partial volume correction using true geometrical information as opposed to model based methods¹⁵ and PET/MRI fingerprinting providing information on tissue metabolic state, structural integrity, perfusion, global/local function and molecular pathways in the same subject¹⁶.

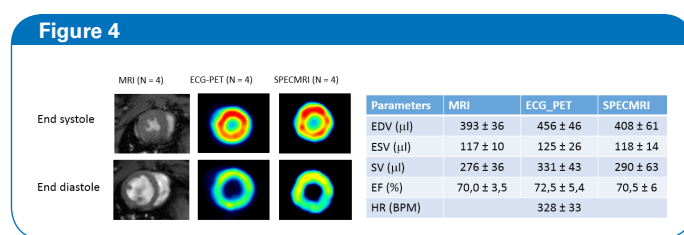


Figure 4: Simultaneous PET/MRI Cardiac imaging in rodents using MRI-based cardiac motion information for retrospective gating (SPECMRI). Representative short axis cardiac images acquired in rats from MRI acquisition (FLASH-IntraGate®), ECG gated PET and PET images generated using MRI information for retrospective gating at end systole and end diastole at mid-papillary muscle level. Comparison of end systolic and end diastolic volumes and ejection fraction between each method.

Conclusion

Bruker's mcPET solutions offers high-translational value(s) for obtaining safe, fast, reliable and non-invasive research results. Its combination with high resolution CT or (ultra) high field MRI open new horizons for true sequential as well as simultaneous investigation of fast evolving disorders such as ischemic/perfusion myocardial injuries.

References

- [1] Bateman, T.M.; Dilsizian, V.; Baenlands, R.S.; DePuey, G.; Heller, G.V.; Wolinsky, D.A. ASNC/SNMMI Position Statement. *J Nucl Cardiol* http://snmmi.files.cms-plus.com/ASNC_SNMMI_Joint_Statment_on_the_Clinical_Indications_for_Myocardial_Perfusion_PET%20-%20FINAL.pdf. 2016
- [2] O'Farrell AC, Evans R, Silvola JM, Miller IS, Conroy E, Hector S, Cary M, Murray DW, Jarzabek MA, Maratha A, Alamanou M, Udupi GM, Shiels L, Pallaud C, Saraste A, Liljenbäck H, Jauhiainen M, Oikonen V, Ducret A, Cutler P, McAuliffe FM, Rousseau JA, Lecomte R, Gascon S, Arany Z, Ky B, Force T, Knuuti J, Gallagher WM, Roivainen A, Byrne. A Novel Positron Emission Tomography (PET) Approach to Monitor Cardiac Metabolic Pathway Remodeling in Response to Sunitinib Malate. *PLoS One*. 2017 Jan 27; 12(1).
- [3] Kashiya N, Miyagawa S, Fukushima S, Kawamura T, Kawamura A, Yoshida S, Harada A, Watabe T, Kanai Y, Toda K, Hatazawa J, Sawa Y. Development of PET Imaging to Visualize Activated Macrophages Accumulated in the Transplanted iPSc-Derived Cardiac Myocytes of Allogeneic Origin for Detecting the Immune Rejection of Allogeneic Cell Transplants in Mice. *PLoS One*. 2016 Dec 8; 11(12).
- [4] Keliher EJ, Ye YX, Wojtkiewicz GR, Aguirre AD, Tricot B, Senders ML, Groenen H, Fay F, Perez-Medina C, Calcagno C, Carlucci G, Reiner T, Sun Y, Courties G, Iwamoto Y, Kim HY, Wang C, Chen JW, Swirski FK, Wey HY, Hooker J, Fayad ZA, Mulder WJ, Weissleder R, Nahrendorf M. Polyglucose nanoparticles with renal elimination and macrophage avidity facilitate PET imaging in ischaemic heart disease. *Nat Commun* 2017 Jan 16; 8: 14064.
- [5] Yang Y, Rendig S, Siegel S, Newport DF, Cherry SR. Cardiac PET imaging in mice with simultaneous cardiac and respiratory gating. *Phys Med Biol*. 2005 Jul 7; 50 (13): 2979-89.
- [6] Hattori N, Bengel FM, Mehilli J, Odaka K, Ishii K, Schwaiger M, Nekolla SG. Global and regional functional measurements with gated FDG PET in comparison with left ventriculography. *Eur J Nucl Med*. 2001 Feb; 28 (2):221-9.
- [7] Cicone F, Viertl D, Quintela Pousa AM, Denoël T, Gnesin S, Scopinaro F, Vozenin MC, Prior JO. Cardiac Radionuclide Imaging in Rodents: A Review of Methods, Results, and Factors at Play. *Front Med*. 2017 Mar 29; 4: 35.
- [8] Weissleder, R. The Future of Molecular Imaging in Systems Biology: Seeing the Whole System, or Not? Fellows Forum, WMIC, New York. 2016.
- [9] Attarwala AA, Karanja YW, Hardiansyah D, Romanó C, Roscher M, Wängler B, Glatting G. Investigation of the imaging characteristics of the ALBIRA II small animal PET system for 18F, 68Ga and 64Cu. *Med Phys*. 2017 Jun; 27 (2): 132-144.
- [10] Wait JM, Tomita H, Burk LM, Lu J, Zhou OZ, Maeda N, Lee YZ. Detection of aortic arch calcification in apolipoprotein E-null mice using carbon nanotube-based micro-CT system. *J Am Heart Assoc*. 2013 Feb 22;2(1):e003358. doi: 10.1161/JAHA.112.003358
- [11] Montet X, Pastor CM, Vallée JP, Becker CD, Geissbuhler A, Morel DR, Meda P. Improved visualization of vessels and hepatic tumors by micro-computed tomography (CT) using iodinated liposomes. *Invest Radiol*. 2007 Sep;42(9):652-8.
- [12] Gonzalez AJ, Aguilar A, Conde P, Hernandez L, Moliner L, Vidal LF, Sanchez F, Sanchez S, Correcher C, Molinos C, Barbera J, Lankes K, Junge S, Bruckbauer T, Bruyndonckx P, Benlloch JM. Silicon PET performance evaluation. *IEEE Trans Nuc Sci* 2016
- [13] Grimm R, Fürst S, Souvatzoglou M, Forman C, Hutter J, Dregely I, Ziegler SI, Kiefer B, Hornegger J, Block KT, Nekolla. Self-gated MRI motion modeling for respiratory motion compensation in integrated PET/MRI. *SGMed Image Anal*. 2015 Jan; 19 (1): 110-20.
- [14] Gsell W, A Nauerth A, Molinos C, Correcher C, Himmelreich U, González A.J, Junge S, Greb T, Polo R, Holvoet B, Deroose CM, Heidenreich M. Simultaneous PET/MRI Cardiac imaging in rodents using MRI-based cardiac motion information for retrospective gating: SPECMRI. *Proceeding of World Molecular Imaging congress; WMIC, Philadelphia*. 2017.
- [15] Dumouchel T, Thorn S, Kordos M, DaSilva J, Beanlands RS, deKemp RA. A three-dimensional model-based partial volume correction strategy for gated cardiac mouse PET imaging. *Phys Med Biol*. 2012 Jul 7; 57 (13): 4309-34.
- [16] Schwaiger M, Kunze K, Rischpler C, Nekolla SG. PET/MR: Yet another Tesla? *J Nucl Cardiol*. 2017 Jun; 24 (3): 1019-1031.